

Introduction

Fusobacterium necrophorum is a pathogen with a well documented disease association with an infective venous thrombophlebitis, known as Lemierre's disease¹. Although other organisms can be causative agents, fusobacteriums are implicated in the main². Normally residing in human oropharyngeal, genitourinary and gastrointestinal tracts spread occurs to adjacent structures and eventually haematogenously. Given the organisms universal sensitivity to penicillin cases are rare but can still occur, especially if presenting late.

We present 2 cases from the Queen Elizabeth University Hospital in Glasgow with *Fusobacterium necrophorum* infections, one of which had the classical Lemierre's picture of a septic thrombophlebitis. At the time of diagnosis they were severely unwell and prompt diagnosis led to appropriate therapy and good outcomes. They both highlighted the destructive nature of the organism and the heightened surveillance required to suspect the disease before a laboratory confirmation can be made.

Case Reports

Case 1

A previously fit and well 22 yr student presented to the emergency department with a sore throat, fever and malaise which had worsened over one week. The pain reached a limit to result in an inability to open her mouth, which led to her admission.

She had a pyrexia of 40°C and was tachycardic but maintained her blood pressure with a normal urine output. There was a left sided neck swelling. Radiological imaging of the chest showed bilateral infiltrates (Fig 1) and she was diagnosed as a severe community acquired pneumonia. Initial treatment was with intravenous co-amoxiclav and oral clarithromycin whilst awaiting blood cultures and respiratory samples.

Her admission blood tests revealed a white cell count of $31.6 \times 10^9/L$ with associated neutrophilia at $30.0 \times 10^9/L$. She was anaemic, thrombocytopenic with normal coagulation, renal and hepatic function.

Blood cultures became positive in the anaerobic bottle only 1 day into admission with gram positive bacilli. Her treatment remained unchanged until the following day when the organism was identified as *Fusobacterium necrophorum*. Following this identification, presentation and likely disease association she had CT imaging of her neck and thorax showing a left retromandibular venous infective thrombosis, reactive cervical lymphadenopathy, small parapharyngeal collections and bilateral pleural effusions (Fig 2). This was in keeping with a diagnosis of Lemierre's disease at which point the clarithromycin stopped and metronidazole added pending sensitivities.

They were confirmed through MIC testing and subsequently she continued on Co-amoxiclav monotherapy and she clinically improved on 2 weeks of treatment. She was subsequently discharged onto Ceftriaxone and metronidazole under OPAT to complete 4 weeks of therapy, with good clinical and biochemical recovery.

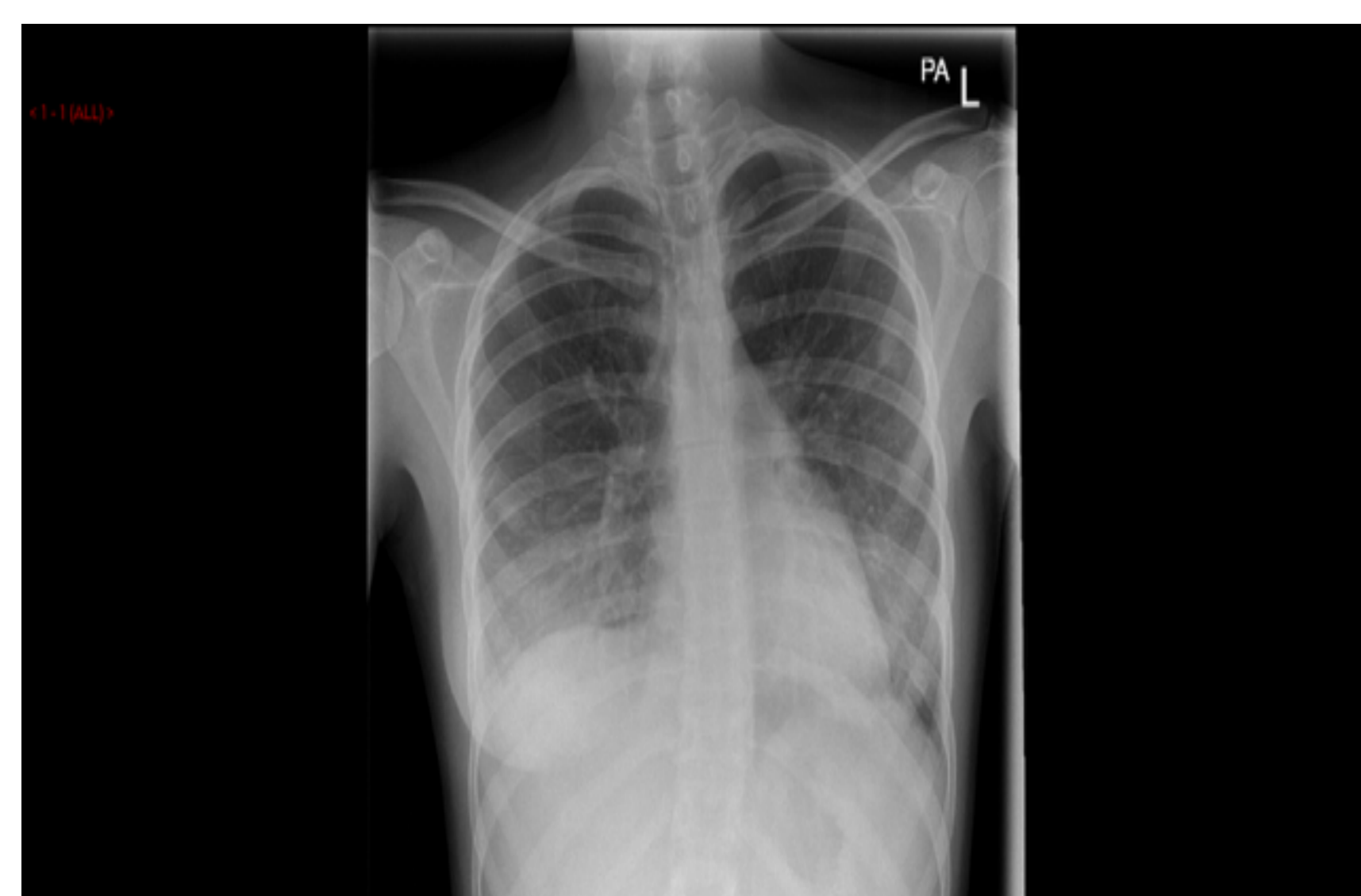

Fig 1

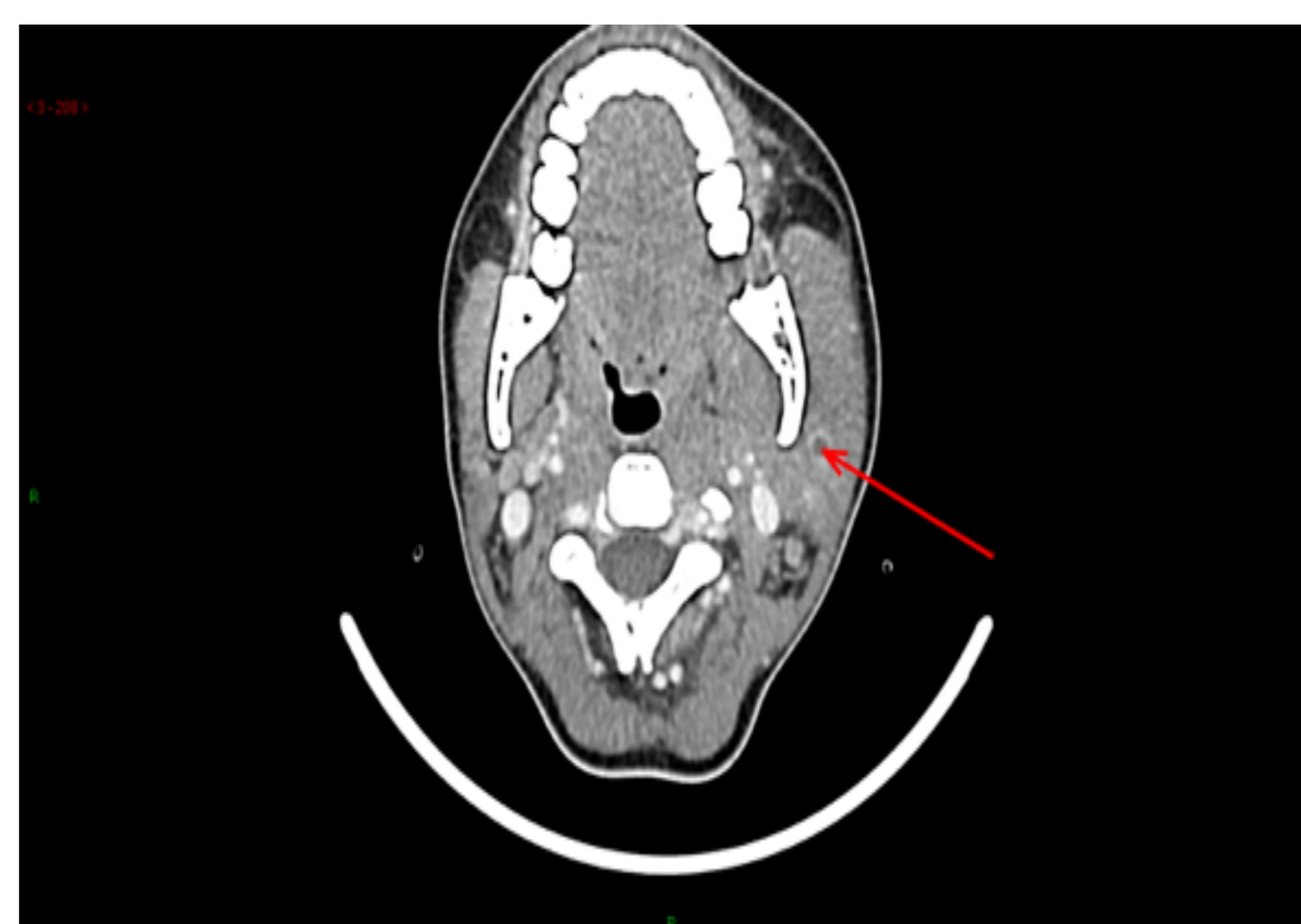

Fig 2

Case 2

A previously well 30 year old presented with a sudden onset of visual impairment which preceded a sudden collapse. This was associated with a two minute seizure activity which was self-limiting. Her clinical background was of increasing right ear pain over the previous week with associated purulent discharge. The pain had persisted despite oral analgesics, however the collapse and seizure activity prompted admission.

On examination she was febrile and haemodynamically stable. She underwent urgent imaging of her head and mastoids revealing mucosal thickening of the right auditory canal consistent with infection/inflammation (Fig 3) with mild oedema of her right temporal lobe representing cerebritis.

She subsequently went to theatre for a right cortical mastoidectomy, washout and myringotomy. Two samples pre and perioperatively grew *Fusobacterium necrophorum*. She was commenced on intravenous Co-amoxiclav and oral metronidazole for 2 weeks followed by oral co-amoxiclav for a further 4 weeks. She remained well clinically and manifested no features of distal spread of disease.

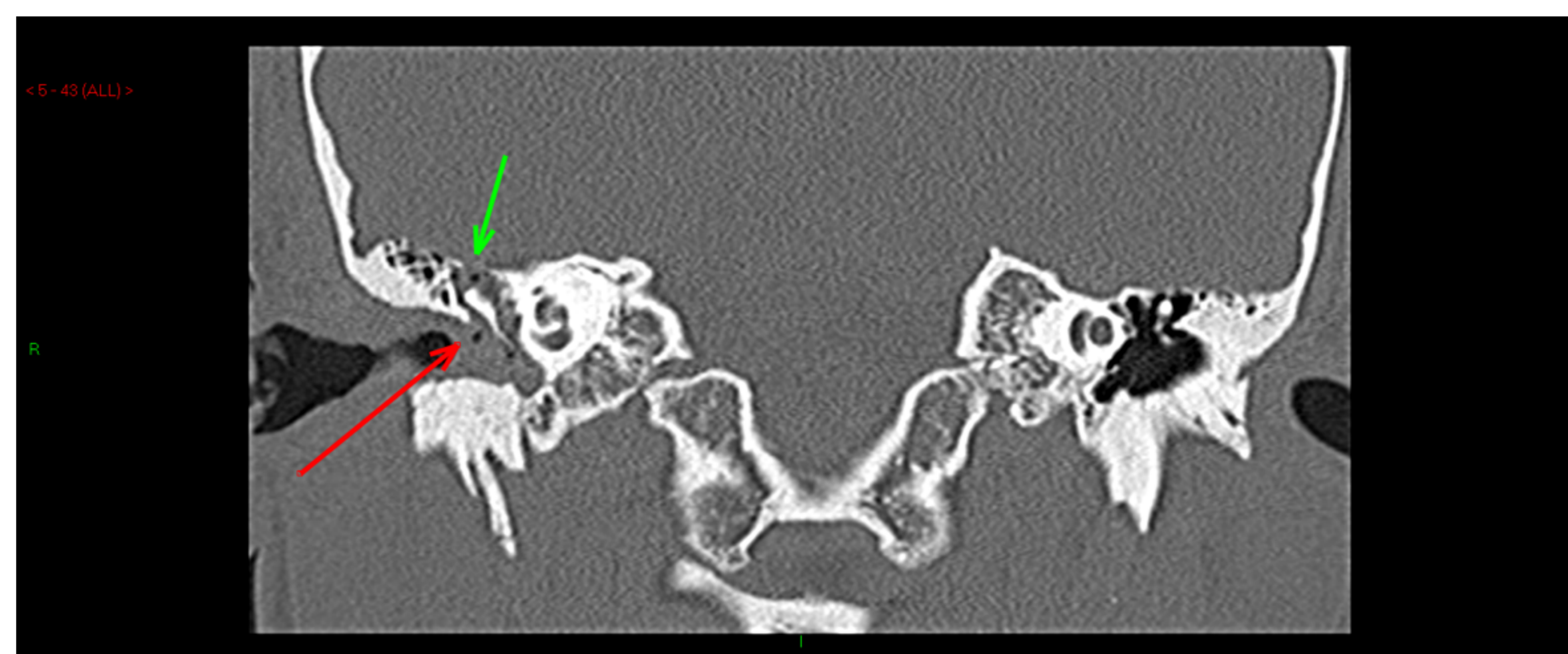


Fig 3: CT mastoid revealing tegumen breakdown and auditory canal thickening/inflammation

Discussion

Fusobacterium necrophorum is an anaerobe normally resident in the oral flora. Once established outwith this environment it can cause toxin-driven destructive and necrotic infections with abscess formation³. Once the abscess ruptures, distal infections ensue with infective internal jugular thrombophlebitis and septic pulmonary emboli manifestations classical for Lemierre's disease.

Infections usually affects young healthy adults, as these two cases illustrate, with the prodromal illness inclusive of a pharyngitis preceding the distal, severe manifestations. This window is paramount to recognise early especially in this cohort of patients; a young adult with pyrexia and severe sore throat should prompt further investigation and consideration of diagnosis.

Obligate anaerobic bacteria are not easy to isolate given the strict conditions required to encourage their growth. Ideally strict anaerobic conditions would be adhered to with immediate dispensation into anaerobic cabinets but this is not always possible due to time pressure and work flow. This further highlights the need for awareness of presentation as at times laboratory diagnosis will not be achieved.

A prolonged treatment plan of intravenous beta lactam and anaerobic cover, with source control, is the recognised best course of action.

Acknowledgements

I would like to thank my consultant colleagues from infectious diseases, Dr Beth White and Dr Macconnachie and from ENT, Ms Lynn Cooke, who were the primary Clinicians involved in these patients care

References

1. Kuppali K, Livorsi D et al. Lemierre's disease due to *Fusobacterium necrophorum*. The Lancet Infectious Diseases. 2012. 12:10 808-815
2. Karkos PD, Arsan S et al. Lemierre's syndrome: A systematic review. The Laryngoscope. 2009. 119:8. 1552-1559
3. Tan ZL, Nagaraja TG et al. *Fusobacterium necrophorum* Infections: Virulence factors, pathogenic mechanism and control measures. Veterinary research communications. 1996. 20:2; 113-140